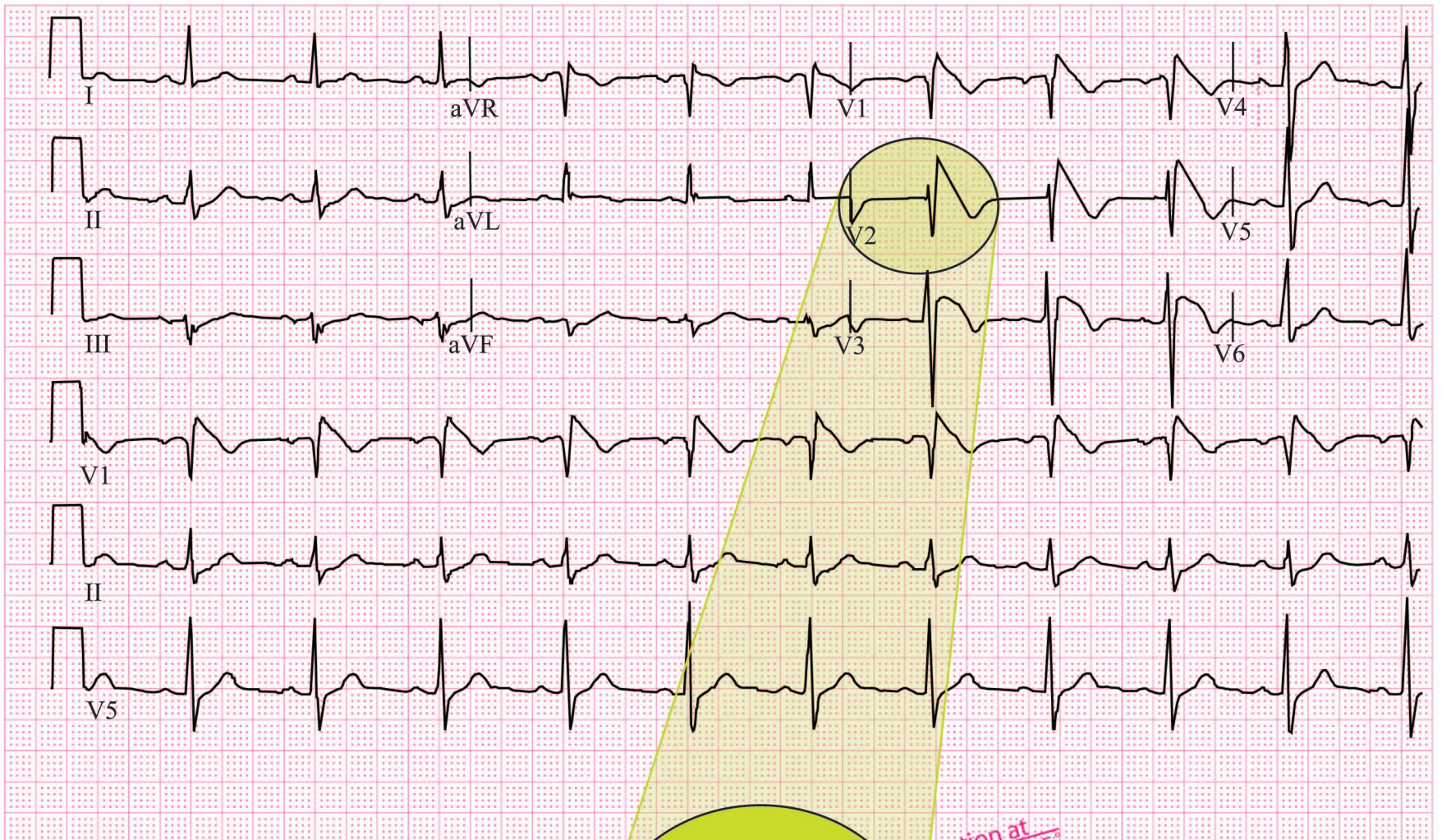


Normal Sinus Rhythm
Incomplete right bundle branch block
ST elevation consider anterior injury
or acute infarct
*** ACUTE MI ***

Computer interpretation NOT correct



© 2006 Vernon R. Stanley, M.D., Ph.D.